

Surgical Repair of Retrograde Type A Aortic Dissection after Thoracic Endovascular Aortic Repair

Chang-Young Kim, M.D., Woo-Ik Chang, M.D., Yeon Soo Kim, M.D., Ji Yoon Ryoo, M.D.

It is expected that the stent graft will become an alternative method for treating aortic diseases or reducing the extent of surgery; therefore, thoracic endovascular aortic repair has widened its indications. However, it can have rare but serious complications such as paraplegia and retrograde type A aortic dissection. Here, we report a surgical repair of retrograde type A aortic dissection that was performed after thoracic endovascular aortic repair.

Key words: 1. Stents
2. Aortic dissection

CASE REPORT

A 75-year-old man visited our emergency department complaining of cough and sputum lasting one month. There was no definite mediastinal widening on a simple chest X-ray, but a prominent aortic arch was observed in comparison to the past two years. A three-dimensional computed tomography scan revealed multiple aneurysmal dilatations with pseudoaneurysm and thrombi in the aortic arch and proximal abdominal aorta. They were measured to be 2.7×1.1 cm (external diameter: 5.1 cm) and 1.5×3.6 cm, respectively, in size. Another focal aneurysmal dilatation was observed in the distal abdominal aorta just above the iliac bifurcation (Fig. 1A). Upon admission, transthoracic echocardiography showed moderate aortic regurgitation and minimal mitral regurgitation without regional wall motion abnormalities. We planned a staged operation (thoracic endovascular aortic repair for aortic arch aneurysm first and aortic valve replacement later) as the patient was considerably old and had poor pulmonary function.

Thoracic endovascular aortic repair (36×100 mm, SEAL

thoracic limb stent graft; S&G Biotech, Seongnam, Korea) was performed as previously described [1]. There was a 12-mm-long landing zone between the left subclavian artery and aortic arch aneurysm with an aortic diameter of 30 mm. Considering the possible type Ib endoleak caused by the mild aneurysmal dilatation of the descending thoracic aorta, we planned to position two overlapping stent grafts strategically (one just distal to the left subclavian artery, and the other covering the descending thoracic aorta). Balloon angioplasty was not performed. The patient was monitored in the intensive care unit postoperatively, transferred to the general ward on the first postoperative day, and discharged on the fifth day without any specific symptoms or signs. No endoleaks were found on the computed tomogram on the second day (Fig. 1B). The patient follow-ups in the outpatient department revealed no symptoms except for the retrograde type A aortic dissection observed on the three-month computed tomogram performed as a routine follow-up study (Fig. 2A).

The patient underwent aortic valve replacement and ascending aorta replacement under deep hypothermic circulatory ar-

Department of Thoracic and Cardiovascular Surgery, Inje University Ilsan Paik Hospital, Inje University College of Medicine

Received: April 15, 2013, Revised: September 12, 2013, Accepted: September 17, 2013

Corresponding author: Woo-Ik Chang, Department of Thoracic and Cardiovascular Surgery, Inje University Ilsan Paik Hospital, Inje University College of Medicine, 170 Juhwa-ro, Ilsanseo-gu, Goyang 411-706, Korea
(Tel) 82-31-910-7365 (Fax) 82-31-910-7614 (E-mail) CWI87@paik.ac.kr

© The Korean Society for Thoracic and Cardiovascular Surgery. 2014. All right reserved.

© This is an open access article distributed under the terms of the Creative Commons Attribution Non-Commercial License (<http://creativecommons.org/licenses/by-nc/3.0>) which permits unrestricted non-commercial use, distribution, and reproduction in any medium, provided the original work is properly cited.

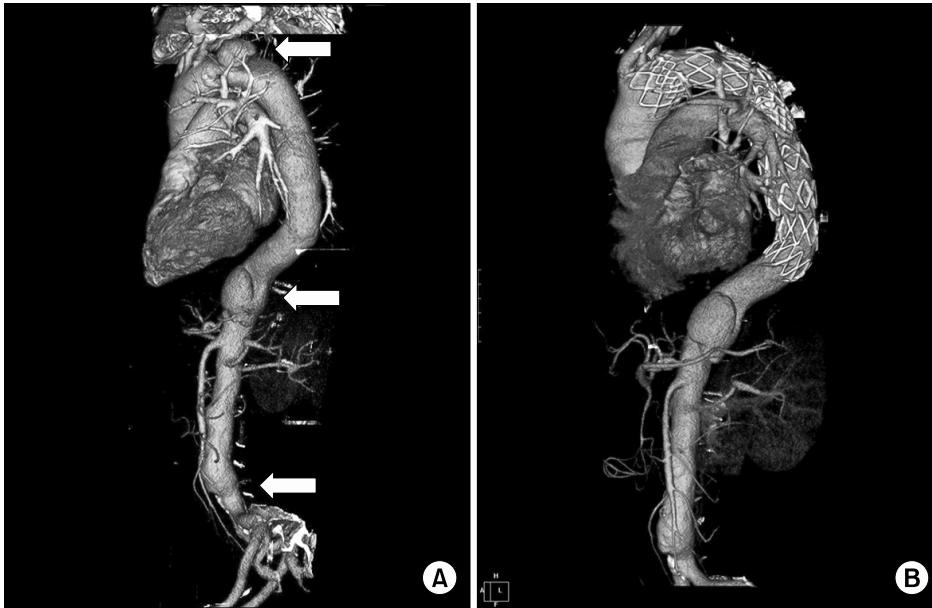

Fig. 1. (A) Preoperative three-dimensional reconstructed computed tomography (CT) image showing the multiple aneurysmal dilatations (arrows) in the aortic arch, proximal abdominal aorta, and distal abdominal aorta just above the iliac bifurcation, and (B) post-stent CT image.

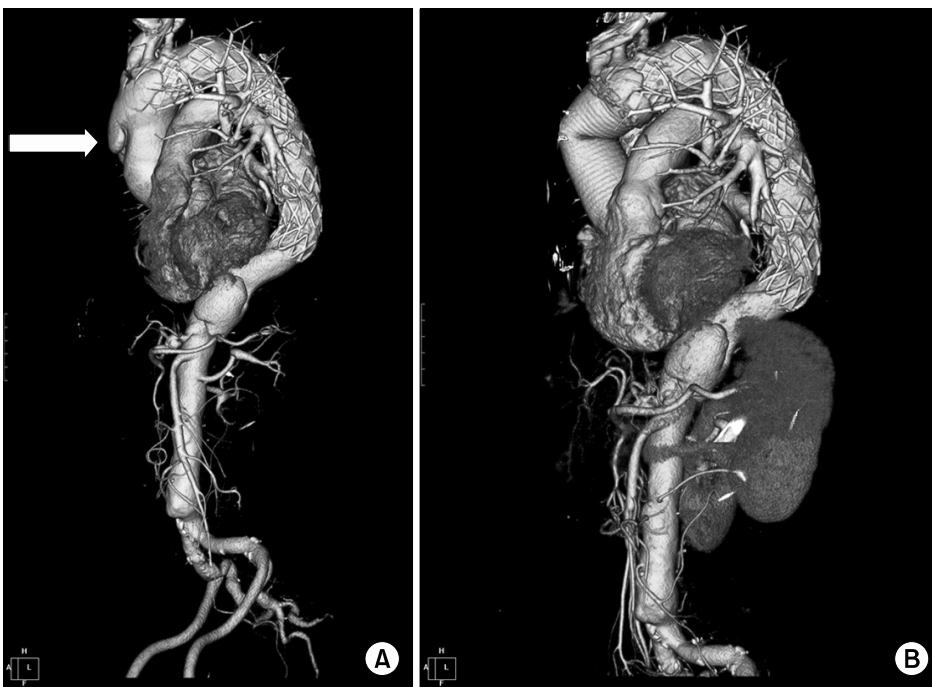


Fig. 2. (A) Computed tomography image showing retrograde type A aortic dissection (arrow) at three months after endovascular repair and (B) last follow-up image at twenty months after the ascending aorta replacement.

rest and selective unilateral antegrade cerebral perfusion. The aortic valve was replaced with a Carpentier-Edwards no 23. tissue valve (Edwards Lifesciences, Irvine, CA, USA). The intimal tear had originated from the bare metal structure in the anterior direction, which was in contact with the anterior wall of the ascending aorta. This bare metal structure was

partially exposed after the excision of the dissected aorta. Distal aortic anastomosis was performed without the removal of the stent graft and reinforced circumferentially with pledgeted sutures. Distal aortic anastomosis sutures partly included the proximal bare metal structure of the stent graft. The pump time, aortic cross clamp time, circulatory arrest time,

and selective antegrade cerebral perfusion time were 234, 144, 40, and 32 minutes, respectively.

The patient was extubated on the first postoperative day, transferred to the general ward on the third postoperative day, discharged on the eighteenth day, and followed up for 24 months without specific symptoms. Endoleaks were observed in the junction of the distal anastomosis site and the bare metal structure of the stent graft on the computed tomogram on the seventh day, but had no significant interval changes on the computed tomogram after 20 months (Fig. 2B).

DISCUSSION

Endovascular stent graft placement is an effectively alternative option in the treatment of various aortic pathologies. As a less invasive treatment option, thoracic endovascular aortic repair has been associated not only with significantly reduced early morbidity and mortality, but also with feasible midterm mortality compared with the open surgical repair of aortic diseases. However, it has some life-threatening and underestimated complications such as retrograde type A aortic dissection and paraplegia.

It has been reported that the incidence of retrograde type A aortic dissection after thoracic endovascular aortic repair ranges from 1.3% to 6.8% [2], and this complication may develop not only in the immediate post-procedural period but also 1,050 days after the procedure with or without specific symptoms [3]. Hong et al. [4] presented two surgical cases of retrograde type A aortic dissection developed within several days after endovascular repair and mentioned that the cardiovascular surgeon should participate in the entire endovascular procedures and follow-up process. In this case, it was detected in computed tomography that was conducted as a routine 3-month follow-up, and the patient had no symptoms.

There are many etiologies associated with the development of retrograde type A aortic dissection after endovascular repair. Khojinezhad and White [2] noted that the potential etiologies of retrograde type A aortic dissection included aortic injury from the catheter and wire or stent graft manipulation, aggressive balloon dilation, inappropriate patient and device selection, oversized stent graft (more than 20%), and poor perioperative antihypertensive control. Eggebrecht et al. [3]

mentioned that the fragile aortic wall (in the patients with acute or chronic aortic dissection and connective tissue disease such as Marfan syndrome and Ehler-Danlos syndrome) and stent graft-related factors (including proximal bare spring and semi-rigid stent graft design) contributed to the occurrence of retrograde type A aortic dissection. These possible causes can be classified as procedure-related, device-related, and related to the natural progression of the disease [3,5]. In this case, we used a self-expandable stent graft with a proximal bare spring and did not perform balloon angioplasty. We assumed that minor trauma on the ascending aorta might have been caused by the repeated subtle motion of the semi-rigid stent graft with the cardiac cycle after implantation [3] or the stress on the greater curvature generated by the spring-back strength of the stent graft [6] and progressed gradually.

In most studies, surgical repair is the only treatment modality. It has been reported that mortality remains high, ranging from 20% to 57% [2,5]. In this case, we did not remove the stent graft during ascending aorta replacement. We assumed that it was a high risk to perform aortic valve replacement and total arch replacement, including the ascending and descending thoracic aorta. Consequently, endoleak remained postoperatively and suggested that the dissecting aortic tissue was not resected completely.

In conclusion, more attention should be paid to the selection of patients, the decision on stent graft type and size, and the manipulation of the wire and sheath because even though the incidence of retrograde type A aortic dissection is low, it can lead to serious results with high mortality. Furthermore, patients with risk factors should be followed more carefully for several years because retrograde type A aortic dissection could develop several years after the procedure.

CONFLICT OF INTEREST

No potential conflict of interest relevant to this article was reported.

REFERENCES

1. Kim CY, Chang WI, Kim YS, Park KT, Ryoo JY. *One-stage management of ascending aorta replacement and percuta-*

- neous endovascular repair for ascending and descending aortic aneurysms: a case report.* Korean J Thorac Cardiovasc Surg 2009;42:524-7.
2. Khojinezhad A, White RA. *Pathogenesis and management of retrograde type A aortic dissection after thoracic endovascular aortic repair.* Ann Vasc Surg 2013;27:1201-6.
 3. Eggebrecht H, Thompson M, Rousseau H, et al. *Retrograde ascending aortic dissection during or after thoracic aortic stent graft placement: insight from the European registry on endovascular aortic repair complications.* Circulation 2009; 120(11 Suppl):S276-81.
 4. Hong S, Kim JH, Lee HJ, Youn YN. *Retrograde aortic dissection after thoracic endovascular aortic repair for descending aorta: 2 case reports.* Korean J Thorac Cardiovasc Surg 2010;43:758-63.
 5. Kpodonu J, Preventza O, Ramaiah VG, et al. *Retrograde type A dissection after endovascular stenting of the descending thoracic aorta. Is the risk real?* Eur J Cardiothorac Surg 2008;33:1014-8.
 6. Dong ZH, Fu WG, Wang YQ, et al. *Retrograde type A aortic dissection after endovascular stent graft placement for treatment of type B dissection.* Circulation 2009;119:735-41.