



증례보고

Case Report :

Recurrence at the hepaticojejunostomy (HJ) site

신지훈 Dr.
Dr. Shin Ji-Hun

서울 아산병원
(Asan Medical Center)
영상의학과, 중증외상팀, 암병원,
간센터, 간암센터, 식도암센터

1

Patient information:

78 year old female patient

2

Symptoms and signs:

Painful swelling in right thigh



CT finding

Large hematoma in right thigh
Contrast leakage in the hematoma → Pseudoaneurysm
Diffuse swelling in pelvis and right thigh
Pleural effusion in both

Procedure

1. CT angiography

2. Femoral angiography

3. Selective angiography

4. Stent-graft placement

Pre-Treatment CT Imaging

Fig1

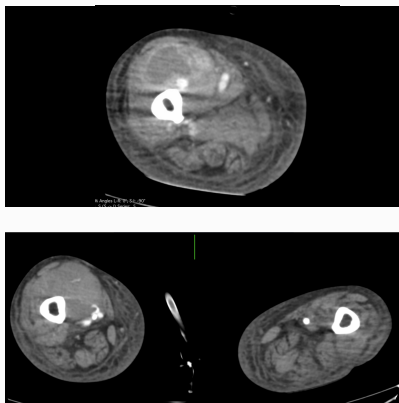


Fig2

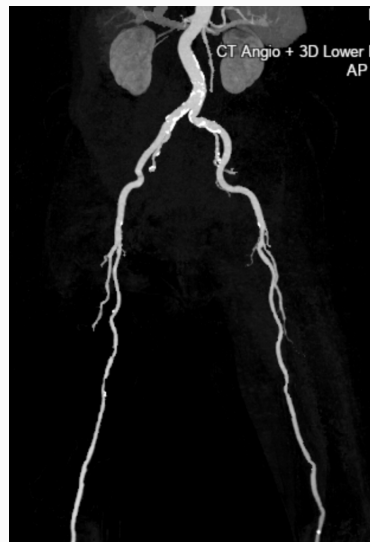
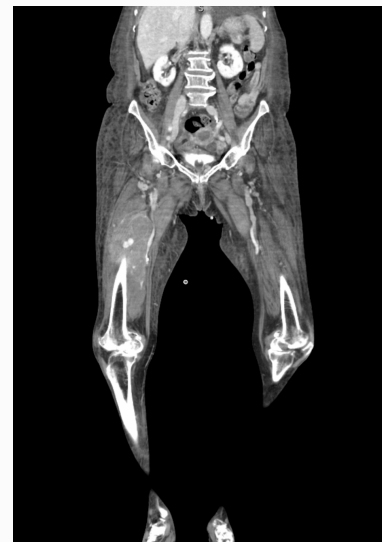
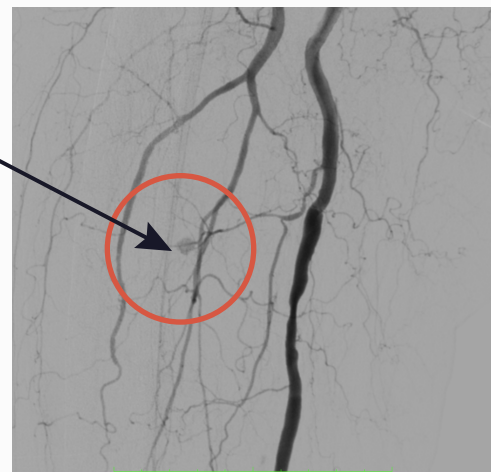
Fig3



Pre-treatment Angiography Exam

Angiographic finding
Small pseudoaneurysm in right thigh in small branch from superficial femoral artery (perforating artery)

Fig4



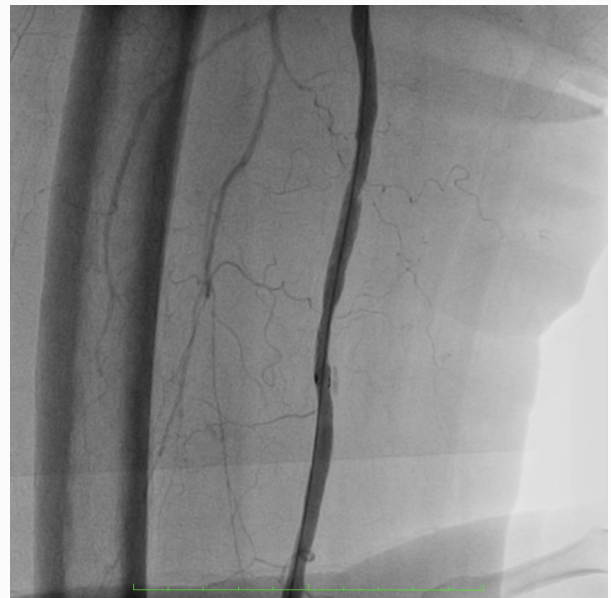Procedure

Selective superficial femoral arteriography showed small contrast leakage from branch vessel of superficial femoral artery

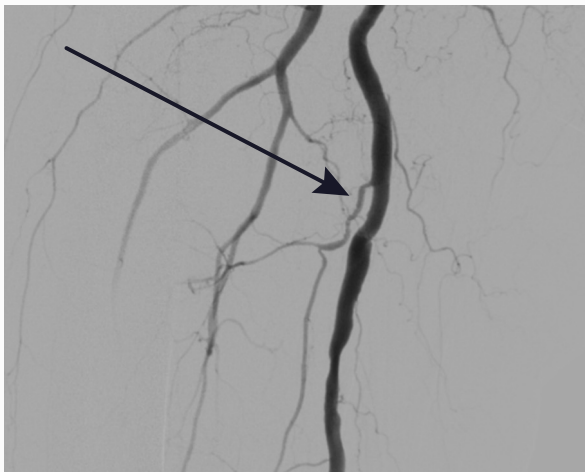
Devices

- E-PTFE stent graft (S&G Biotech Inc. Yongin, Korea)
- 8mm 6cm
- 6mm PTA balloon catheter

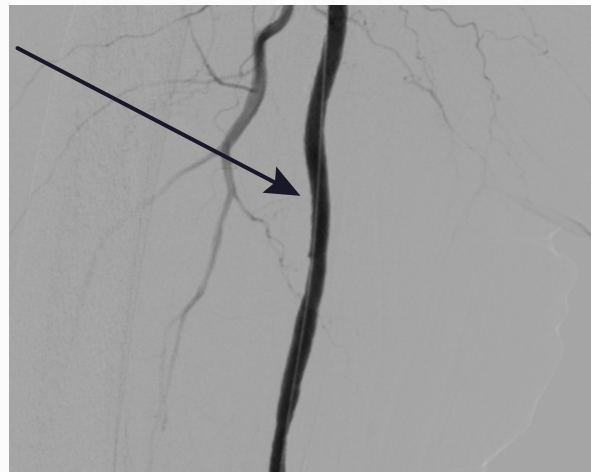After e-PTFE stent graft placement, contrast leakage was not detected.



BEFORE



AFTER





"For leading edge innovation
in the medical device industry
Creating a better world"

REFERENCES

1. Takatoshi Koroki, Takuya Kuroki, Tomohiro Abe, Eiji Furukoji, Hidenobu Ochiai et al. Successful covered stent-graft treatment of superficial femoral arterial injury due to blunt trauma. *Endosc Int Open*. 2021 Mar 12;8(1):e639. doi: 10.1002/ams2.639.ecollection Jan-Dec 2021

2. Sean Degmetich, Megan Brenner, Matthew Firek, Bishoy Zakhaty, Bruno C Coimbra, Raul Coimbra et al. Endovascular repair is a feasible option for superficial femoral artery injuries: a comparative effectiveness analysis. *Endosc Int Open*. 2020 nov 5. doi: 10.1007/s00068-020-01536-5.



S&G Biotech Inc | 82 Bugok-ro, Pogok-eup, Cheoin-Gu, Yongin-si, Gyeonggi-do, South Korea [17023]
Tel. +82. 31. 748. 6625 | Fax. +82. 31. 748. 6620

www.sngbio.co.kr